UpToDate® Official reprint from UpToDate®
www.uptodate.com ©2019 UpToDate, Inc. and/or its affiliates. All Rights Reserved.

Wolters Kluwer

Causes of upper gastrointestinal bleeding in adults

Author: Don C Rockey, MD
Section Editor: Mark Feldman, MD, MACP, AGAF, FACG
Deputy Editor: Anne C Travis, MD, MSc, FACG, AGAF

All topics are updated as new evidence becomes available and our peer review process is complete.

Literature review current through: Sep 2019. | **This topic last updated:** Sep 11, 2018.

INTRODUCTION

Upper gastrointestinal bleeding (UGIB) is a common medical condition that results in substantial morbidity, mortality, and medical care cost. It commonly presents with hematemesis (vomiting of blood or coffee ground-like material) and/or melena (black, tarry stools). In 5 to 10 percent of patients with severe UGIB, it may present as hematochezia.

This topic will review the different causes of UGIB. The approach to the diagnosis and management of patients with UGIB, as well as more detailed discussions of some specific causes of UGIB, are discussed separately:

- (See "Approach to acute upper gastrointestinal bleeding in adults".)
- (See "Peptic ulcer disease: Clinical manifestations and diagnosis".)
- (See "Overview of the treatment of bleeding peptic ulcers".)
- (See "Overview of the management of patients with variceal bleeding".)
- (See "Portal hypertensive gastropathy".)
- (See "Angiodysplasia of the gastrointestinal tract".)
- (See "Mallory-Weiss syndrome".)

EPIDEMIOLOGY

The annual incidence of hospitalization for acute upper gastrointestinal bleeding (UGIB) in the United States is approximately 65 per 100,000 individuals and is more common than lower GI bleeding [1]. The hospitalization rate for UGIB is estimated to be sixfold higher than for lower GI bleeding [2,3]. The incidence of UGIB is higher in men than in women (128 versus 65 per 100,000 in one study) and increases with age. The reported frequencies of specific causes of UGIB vary and have changed over time [4-9]. (See 'Differential diagnosis' below.)

Older studies suggested that peptic ulcer disease was responsible for approximately half of UGIB, but more recent studies suggest that while still prominent, ulcer disease is now a less common cause (approximately 20 to 25 percent of cases) [4,5,7] and other disorders such as esophagitis are becoming comparatively

more common. Among patients with bleeding peptic ulcers, gastric ulcers are more common than duodenal ulcers [4,7].

DIFFERENTIAL DIAGNOSIS

Upper gastrointestinal bleeding (UGIB) can be classified into several broad categories based on anatomic and pathophysiologic factors (table 1). From a pathophysiologic perspective, ulcerative and erosive lesions (gastric or duodenal ulcers, esophagitis, and gastritis) are far more common than vascular lesions (varices, angiodysplasia), mass lesions (adenocarcinoma, polyps), or traumatic lesions (Mallory-Weiss tear). Of note, the source of bleeding cannot be identified in 10 to 15 percent of patients with UGIB, probably because the culprit lesion is either difficult to identify (such as a Dieulafoy's lesion), obscured by retained blood clot at endoscopy, or because the culprit lesion healed by the time endoscopy was performed.

The most common causes of UGIB include the following (in approximate descending order of frequency) [1,4-6,9,10]:

- Gastric and/or duodenal ulcers
- Severe or erosive gastritis/duodenitis
- Severe or erosive esophagitis
- Esophagogastric varices
- Portal hypertensive gastropathy
- Angiodysplasia (also known as vascular ectasia)
- Mallory-Weiss syndrome
- Mass lesions (polyps/cancers)
- No lesion identified (10 to 15 percent of patients)

Other less common causes of UGIB include:

- Dieulafoy's lesion
- Gastric antral vascular ectasia
- Hemobilia
- Hemosuccus pancreaticus
- Aortoenteric fistula
- Cameron lesions
- Ectopic varices
- Iatrogenic bleeding after endoscopic interventions

SPECIFIC CAUSES

The most common causes of upper gastrointestinal bleeding (UGIB), gastroduodenal ulcer disease, severe or erosive esophagitis, and esophagogastric varices, remain pervasive in medicine. Accompanying symptoms (ulcer disease may be associated with pain or anorexia, while esophagitis may be associated with reflux symptoms), severity of bleeding (ulcers with bleeding arteries or varices typically bleed most aggressively), and type of bleeding (hematochezia plus hematemesis typically is caused by vascular lesions), may provide clues as to the diagnosis (table 1). However, in most patients, it is not possible to

predict the cause of bleeding based on clinical grounds alone, and endoscopy is required to make a definitive diagnosis [11]. (See "Approach to acute upper gastrointestinal bleeding in adults", section on 'Diagnostic studies'.)

Peptic ulcer disease — Gastroduodenal ulcers are a common cause of UGIB (picture 1A-B and picture 2 and movie 1) [12,13]. The four major risk factors for bleeding peptic ulcers are [14,15] (see "Peptic ulcer disease: Epidemiology, etiology, and pathogenesis" and "Unusual causes of peptic ulcer disease"):

- *Helicobacter pylori* infection
- Nonsteroidal anti-inflammatory drugs (NSAIDs)
- Physiologic stress
- Excess gastric acid

Reduction or elimination of these risk factors reduces ulcer recurrence and rebleeding rates [16-19].

- ***H. pylori*** – *H. pylori* is a spiral bacterium that infects the superficial gastric mucosa and disrupts the mucous layer, making the mucosa more susceptible to acid damage. (See "Pathophysiology of and immune response to Helicobacter pylori infection".)

  The chronic inflammation induced by *H. pylori* upsets gastric secretory physiology to varying degrees and leads to chronic gastritis that, in most individuals, is asymptomatic and does not progress. In some cases, however, altered gastric secretion coupled with tissue injury leads to peptic ulcer disease [20-23]. (See "Treatment regimens for Helicobacter pylori".)

- **NSAIDs** – NSAIDs, including low-dose aspirin, commonly predispose to ulceration in the GI tract [3,24,25]. NSAID-induced injury results from both local effects and systemic prostaglandin inhibition. The majority of these ulcers are asymptomatic and uncomplicated. However, older adults with a prior history of bleeding ulcer disease are at increased risk for recurrent ulcers and complications [26-28]. NSAIDs have also been implicated as an important factor for nonhealing ulcers [29]. (See "NSAIDs (including aspirin): Pathogenesis of gastroduodenal toxicity".)

- **Stress** – Stress-related ulcers are a common cause of acute UGIB in patients who are hospitalized for life-threatening non-bleeding illnesses. Patients with these secondary episodes of bleeding have a higher mortality than those admitted to the hospital with primary UGIB [30]. The risk of stress ulcer bleeding is increased in patients with respiratory failure and those with a coagulopathy. (See "Stress ulcers in the intensive care unit: Diagnosis, management, and prevention".)

  The psychologic stress that is commonly associated with life events and/or psychological factors has not clearly been associated with gastroduodenal ulcer disease, and acid reduction therapy is not routinely indicated in this situation.

- **Gastric acid** – Gastric acid and pepsin are essential cofactors in the pathogenesis of peptic ulcers. Impairment of mucosal integrity by factors such as *H. pylori*, NSAIDs, or physiologic stress leads to increased cell membrane permeability to back diffusion of hydrogen ions, resulting in intramural acidosis, cell death, and ulceration. Rarely, hyperacidity is the sole cause of peptic ulceration, as in patients with Zollinger-Ellison syndrome. Control of gastric acidity is considered an essential therapeutic maneuver in patients with active UGIB. (See "Zollinger-Ellison syndrome (gastrinoma):

Clinical manifestations and diagnosis" and "Approach to acute upper gastrointestinal bleeding in adults".)

A sizeable body of literature suggests that gastroduodenal ulcers associated with different risk factors behave different clinically [12,13,31,32]. In a recent large study of patients from North America with gastroduodenal ulcers, approximately half had evidence of *H. pylori* infection and half did not [33]. The lowest rate of rebleeding and mortality was observed in patients with *H. pylori*-positive ulcers. Patients with *H. pylori*-negative ulcers had poorer outcomes, regardless of use of NSAIDs. Patients with ulcers negative for *H. pylori* and no history of NSAID use had the worst outcomes and more severe systemic disease.

Esophagitis — Esophagitis is a common cause of upper GI pathology and bleeding. In a large cohort of patients with UGIB, 13 percent of patients had esophagitis [6], similar to the number of patients with duodenal ulcers (12 percent). Patients with erosive esophagitis often have a history of gastroesophageal reflux disease (GERD) [34]. Other risk factors include medication use (eg, NSAIDS, oral bisphosphonates, tetracycline) and infections (eg, *Candida*, herpes simplex virus). (See "Clinical manifestations and diagnosis of gastroesophageal reflux in adults" and "Medication-induced esophagitis" and "Herpes simplex virus infection of the esophagus" and "Clinical manifestations of oropharyngeal and esophageal candidiasis" and "AIDS-related cytomegalovirus gastrointestinal disease", section on 'Esophagitis'.)

Hematemesis appears to be more common in patients with bleeding from esophagitis than in patients with bleeding from other sources (86 versus 55 percent in one study) [34]. Conversely, melena appears to be less common (38 versus 68 percent, respectively).

Compared with patients with UGIB due to other causes, patients with UGIB due to esophagitis often have a more benign course, with shorter hospital stays, lower rebleeding rates, and lower mortality rates [34]. Treatment of bleeding esophagitis involves acid suppression, endoscopic therapy (rarely required), and treatment/removal of risk factors for GERD. (See "Medical management of gastroesophageal reflux disease in adults".)

Gastritis/gastropathy and duodenitis/duodenopathy — Gastritis and duodenitis are predominantly inflammatory processes. The terms "gastritis" and "duodenitis" are used to denote inflammation-associated mucosal injury. However, epithelial cell injury and regeneration are not always accompanied by mucosal inflammation. This distinction has caused considerable confusion since the terms "gastritis" and "duodenitis" are often used to describe endoscopic or radiologic characteristics of the mucosa rather than specific histologic findings. Epithelial cell damage and regeneration with minimal or no associated inflammation are properly referred to as "gastropathy" or "duodenopathy." (See "Gastritis: Etiology and diagnosis".)

Gastritis and duodenitis are commonly identified at the time of endoscopy, but rarely lead to significant UGIB (note that they are, in fact, often identified at the time of endoscopy and may be commented on). Such commonly identified trivial endoscopic abnormalities are typically not the cause of (significant) UGIB in the absence of other factors such as anticoagulation or a coagulopathy. A careful examination for commonly missed lesions is essential in patients with clinically significant blood loss in whom the endoscopic examination reveals only gastritis or duodenitis. The examination should include careful inspection for ulcers in unusual places, varices, and Dieulafoy's lesions, all of which may be difficult to identify.

A multitude of disorders and exposures are associated with gastritis and duodenitis. Many of the associated disorders or exposures are also risk factors for peptic ulcer disease [35,36] (see 'Peptic ulcer disease'

above). Other risk factors include excessive alcohol consumption, radiation injury, obesity surgery, and chronic bile reflux. Gastritis may also be found in certain autoimmune diseases. Bleeding in patients with gastritis/gastropathy or duodenitis/duodenopathy is more common in the setting of anticoagulant use. (See "Gastritis: Etiology and diagnosis" and "Acute and chronic gastritis due to Helicobacter pylori".)

The differential diagnosis of acute gastritis includes gastric antral vascular ectasia (GAVE) and, in particular, portal hypertensive gastropathy (PHG). PHG should be suspected in patients with cirrhosis with or without overt evidence of portal hypertension, in patients with proximal greater than distal gastric involvement, and in patients with concomitant varices. GAVE typically has a unique endoscopic appearance with linear aggregates of petechiae in the antrum, giving the antral area the appearance of a watermelon rind. (See "Portal hypertensive gastropathy" and 'Gastric antral vascular ectasia' below.)

The diagnosis of gastritis and duodenitis is made almost exclusively by endoscopic evaluation of the mucosa. Although typically not necessary in the setting of acute bleeding, the diagnosis can be confirmed by biopsy and histologic evaluation. Histologic findings can vary over a wide spectrum, ranging from epithelial hyperplasia to extensive epithelial cell damage with infiltration by inflammatory cells. (See "Gastritis: Etiology and diagnosis", section on 'Diagnosis'.)

Bleeding from gastritis or duodenitis is typically self-limited. Treatment includes removing the causative agent, a limited course of acid suppression with a proton pump inhibitor, withholding anticoagulants when they may be contributing (if possible), and, if bleeding is severe, endoscopic therapy with modalities such as argon plasma coagulation. (See "Treatment regimens for Helicobacter pylori" and "NSAIDs (including aspirin): Treatment of gastroduodenal toxicity".)

Complications of portal hypertension — Several causes of UGIB are the result of portal hypertension, including esophageal varices, PHG, gastric varices, and ectopic varices. However, it should be kept in mind that patients with portal hypertension can develop UGIB from sources unrelated to portal hypertension (eg, peptic ulcer disease). In one study, approximately 40 percent of patients with cirrhosis and UGIB had a cause unrelated to portal hypertension [37].

While most patients with portal hypertension have cirrhosis, portal hypertension can also occur in the absence of cirrhosis, a condition referred to as "noncirrhotic portal hypertension." Causes of noncirrhotic portal hypertension include portal vein thrombosis, schistosomiasis, and idiopathic noncirrhotic portal hypertension. Additionally, portal hypertension and associated variceal bleeding can occur as a result of thrombosis of mesenteric vessels. (See "Noncirrhotic portal hypertension".)

Varices — Varices (picture 3A-B and picture 4) develop as a consequence of portal hypertension in approximately 50 percent of patients with cirrhosis, and variceal hemorrhage occurs at an annual rate of 5 to 15 percent [38]. The onset of UGIB from varices usually signifies significant portal hypertension, which is typically associated with advanced liver disease (Child-Pugh class B or C). Patients who develop bleeding while being treated with a beta blocker have a poor prognosis [39]. The clinical presentation of patients with varices, which most commonly manifests as hematemesis and/or melena, may be similar to that seen in patients with bleeding from nonvariceal lesions [37]. Indeed, differentiating variceal from nonvariceal bleeding based on clinical grounds, even in patients with known cirrhosis, is often difficult if not impossible.

Varices may be identified in the esophagus and/or the stomach. They may also be seen at sites other than the esophagus or stomach, such as the small bowel (ectopic varices). Isolated gastric varices can result

from segmental portal hypertension due to splenic vein thrombosis, which results from injury to the splenic vein due to pancreatitis, pancreatic carcinoma, or trauma in the left upper quadrant (picture 4). Risk factors for variceal hemorrhage include increasing severity of liver disease, increasing Child-Pugh class, variceal size, and the presence of red wale markings on varices [40,41]. (See "Prediction of variceal hemorrhage in patients with cirrhosis", section on 'Predictive factors'.)

As with most other causes of UGIB, endoscopy is the diagnostic modality of choice for esophagogastric varices. Ectopic varices may be detected with methods such as angiography or video capsule endoscopy. (See "Approach to acute upper gastrointestinal bleeding in adults", section on 'Diagnostic studies'.)

Various treatments are available for acute hemostasis of esophageal variceal hemorrhage [38]. Endoscopic band ligation is the standard treatment, with sclerotherapy used in situations where band ligation is not technically feasible. Early transjugular intrahepatic portosystemic shunt (TIPS) placement may be appropriate for some patients with gastroesophageal variceal bleeding [42]. (See "Methods to achieve hemostasis in patients with acute variceal hemorrhage", section on 'Management of esophageal varices'.)

The only mechanical technique considered to be highly effective for treating gastric varices is injection with some form of cyanoacrylate (glue). Techniques used on other lesions, such as injection with epinephrine and cautery are generally not effective and should be avoided. TIPS and balloon-occluded retrograde transvenous obliteration (BRTO) techniques may also be effective in some patients [43]. Banding may be possible if the varices are near the gastroesophageal junction, but is generally not effective in gastric varices. (See "Methods to achieve hemostasis in patients with acute variceal hemorrhage", section on 'Management of gastric varices'.)

TIPS, BRTO, or surgical shunting are typically needed to treat bleeding ectopic varices and should only be performed in consultation with experts. (See "Methods to achieve hemostasis in patients with acute variceal hemorrhage", section on 'Management of ectopic varices'.)

Portal hypertensive gastropathy — PHG (congestive gastropathy), while extremely common in patients with portal hypertension, is an uncommon cause of significant bleeding in these patients. When PHG is the sole cause of bleeding, there is diffuse mucosal oozing with no other lesions, such as varices, to account for the GI bleeding and anemia. The mucosa is friable, and bleeding presumably occurs when the ectatic vessels rupture. The severity of gastropathy is related to the level of portal pressure, the level of hepatic vascular resistance, and the degree of reduction in hepatic blood flow. PHG, which most often causes occult bleeding [44], is discussed in detail elsewhere. (See "Portal hypertensive gastropathy".)

PHG may be confused with GAVE, which is also seen in patients with cirrhosis. (See 'Gastric antral vascular ectasia' below.)

Vascular lesions — Vascular lesions in the GI tract that may cause bleeding include angiodysplasias, Dieulafoy's lesions, and GAVE.

Angiodysplasia — Angiodysplasias are the most common vascular anomalies encountered in the GI tract. Angiodysplasia of the stomach or duodenum has been incriminated as the cause of blood loss in 4 to 7 percent of patients with GI bleeding [45-47]. Such patients may present with either occult bleeding or overt bleeding [44]. Angiodysplasia is usually diagnosed by endoscopy, but in some cases, radiographic imaging or surgery may be required for detection.

Angiodysplasias of the GI tract are discussed in detail elsewhere. (See "Angiodysplasia of the gastrointestinal tract".)

Dieulafoy's lesion — A Dieulafoy's lesion is a dilated aberrant submucosal vessel that erodes the overlying epithelium in the absence of a primary ulcer (picture 5) [10]. The submucosal artery does not undergo normal branching within the wall of the stomach. As a result, the caliber of the artery is in the range of 1 to 3 mm, approximately 10 times the normal caliber of mucosal capillaries. Dieulafoy's lesions are usually located in the proximal stomach along the lesser curvature, near the esophagogastric junction (typically within 5 cm), although they have been found in all areas of the GI tract, including the esophagus, duodenum, and colon [10,48-51].

The etiology of Dieulafoy's lesion is unknown. Additionally, events triggering bleeding are not well understood. Patients who bleed from Dieulafoy's lesions are typically men with comorbidities including cardiovascular disease, hypertension, chronic kidney disease, diabetes, or alcohol abuse [51]. The use of NSAIDS is also common among patients with Dieulafoy's lesions; one theory is that NSAIDS incite bleeding by causing mucosal atrophy and ischemic injury [10]. Bleeding episodes are often self-limited, although bleeding can be recurrent and profuse.

Endoscopy is the diagnostic modality of choice to detect a Dieulafoy's lesion and is particularly helpful when performed during acute bleeding [52,53]. This is because active arterial pumping may be visualized in an area without an associated ulcer or mass lesion. In the absence of active bleeding, a Dieulafoy's lesion may appear as a raised nipple or visible vessel without an associated ulcer; however, the aberrant vessel may not be seen unless there is active bleeding from the site. Because a Dieulafoy's lesion can be difficult to identify, it should be considered in the differential diagnosis of bleeding without a clear source. Endoscopic ultrasonography may be useful in confirming the diagnosis [53]. (See "Evaluation of suspected small bowel bleeding (formerly obscure gastrointestinal bleeding)", section on 'Etiology'.)

A number of approaches have been shown to be effective for the treatment of Dieulafoy's lesions. Endoscopic hemostasis may be achieved with a combination of epinephrine injection followed by bipolar probe coagulation (picture 6), heater probe thermal coagulation, or hemoclip placement [54-56].

Other approaches that have been used successfully to treat Dieulafoy's lesions include endoscopic band ligation, argon plasma coagulation, and cyanoacrylate injection [55,57-61]. However, endoscopic band ligation should be used with caution in this setting because it has been associated with perforation (especially when performed where the gastric wall is thin, such as the fundus) and bleeding from the resulting ulcer once the band falls off; a fatality from such an ulcer has been reported [54,57]. Similarly, band ligation is probably unsafe in the small bowel and right colon, since it may entrap the serosa and thereby lead to perforation [62]. (See "Overview of the treatment of bleeding peptic ulcers", section on 'Endoscopic therapy'.)

Doppler ultrasound has been used to confirm ablation of a Dieulafoy's lesion by documenting the absence of blood flow following treatment [63]. Endoscopic tattooing is helpful for locating the lesion for further endoscopic retreatment or intraoperative wedge resection (picture 6). (See "Tattooing and other methods for localizing gastrointestinal lesions".)

If rebleeding recurs after one endoscopic treatment, therapeutic options include repeat endoscopic hemostasis, angiographic embolization, or surgical wedge resection of the lesion. A combined endoscopic

and laparoscopic approach has been described; this approach allows precise location of the lesion with intraoperative endoscopy, followed by a limited laparoscopic surgical wedge resection. There is no further risk of rebleeding from a Dieulafoy's lesion after surgical wedge resection. (See "Angiographic control of nonvariceal gastrointestinal bleeding in adults".)

Few studies have compared the various treatment approaches, so treatment should be based upon local experience and expertise. In most instances, the initial approach to rebleeding should be aggressive endoscopy and/or angiography. Surgical resection should be reserved for difficult-to-control bleeding.

Gastric antral vascular ectasia — GAVE, or watermelon stomach, is an uncommon cause of UGIB that is often confused with PHG, both of which can occur in patients with cirrhosis [64]. (See "Portal hypertensive gastropathy".)

The term "watermelon stomach" is derived from the characteristic endoscopic appearance of longitudinal rows of flat, reddish stripes radiating from the pylorus into the antrum that resemble the stripes on a watermelon (picture 7) [9]. The red stripes represent ectatic and sacculated mucosal vessels. A punctate form (in which the red stripes are not apparent) has also been described and appears to be more common in patients with underlying cirrhosis [65]. While acute bleeding may occur, low-grade GI bleeding is more common, often with iron deficiency anemia. It is uncommon for patients to present with acute and massive bleeding.

GAVE is usually an isolated problem but has been associated with cirrhosis and systemic sclerosis [64]. In one series of 744 consecutive patients with nonvariceal UGIB, bleeding was due to GAVE in 4 percent [66]. Portal hypertension was present in 31 percent of the patients with GAVE in this cohort. The most common clinical profile of a patient with GAVE is an older (>70 years old) woman. In the series described above, for example, the median age was 74 years, and 80 percent of the patients were women [66].

Patients may also present with acute bleeding. The clinical presentation is similar whether portal hypertension is present or not, except that those with portal hypertension may have diffuse antral angiomas rather than the classic linear pattern [66].

The diagnosis is based on the classic endoscopic appearance. It may be confirmed with endoscopic biopsy, endoscopic ultrasound, tagged red blood cell scan, or computed tomography (CT) scan [67]. Histopathologically, GAVE is characterized by vascular ectasia, spindle cell proliferation, and fibrohyalinosis (picture 8) [64].

Episodic transfusions are required in some patients. Endoscopic coagulation with a heater probe, bipolar probe, argon plasma coagulator, laser therapy, or radiofrequency ablation obliterates the vascular ectasia and decreases the degree of bleeding (picture 9A-B) [66,68]. (See "Argon plasma coagulation in the management of gastrointestinal hemorrhage".)

Portal decompression with TIPS does **not** reliably reduce bleeding, underscoring the uncertain relationship of GAVE to portal hypertension [69,70]. Antrectomy prevents recurrent bleeding but is usually reserved for patients who fail endoscopic therapies. Combination estrogen/progesterone therapy may decrease bleeding, although the ectatic vessels appear to persist [71].

Trauma or iatrogenic — Traumatic or iatrogenic causes of UGIB include Mallory-Weiss syndrome, Cameron lesions in patients with a hiatal hernia, aortoenteric fistulas, foreign body ingestion, postsurgical

anastomotic bleeding, and postpolypectomy bleeding.

Mallory-Weiss syndrome — Mallory-Weiss syndrome is characterized by longitudinal mucosal lacerations (intramural dissections) in the distal esophagus and proximal stomach that are usually associated with forceful retching. The lacerations often lead to bleeding from submucosal arteries. The prevalence of such tears among patients presenting with UGIB is approximately 5 percent [72-74]. The amount of blood loss is usually small and self-limited. However, massive hemorrhage requiring transfusions and even leading to death can occur [75].

Mallory-Weiss tears are usually secondary to a sudden increase in intra-abdominal pressure. Precipitating factors include vomiting, straining at stool or lifting, coughing, seizures, hiccups under anesthesia, closed-chest massage, blunt abdominal injury, colonoscopic preparation with polyethylene glycol electrolyte lavage solution, and gastroscopy [72-74,76-79]. (See "Mallory-Weiss syndrome", section on 'Etiology and pathogenesis'.)

Endoscopy is the diagnostic modality of choice to document the presence of a gastroesophageal tear. Most tears heal spontaneously [80,81]. Endoscopic therapy is the first-line treatment for actively bleeding lacerations. Several hemostatic methods have been used to control bleeding, including injection of epinephrine, thermal coagulation, hemoclip placement, and endoscopic band ligation. (See "Mallory-Weiss syndrome", section on 'Diagnosis' and "Mallory-Weiss syndrome", section on 'Treatment of persistent and recurrent bleeding'.)

Cameron lesions — Cameron lesions are erosions or ulcers occurring in the sac of a hiatal hernia [82-84]. They have been described in up to 5 percent of patients with a hiatal hernia who undergo upper endoscopy [84]. They are usually an incidental finding, but they rarely cause acute or massive UGIB. They may also cause chronic bleeding leading to iron deficiency anemia [85-89]. Although their pathogenesis is incompletely understood, potential contributing factors include reflux esophagitis and mechanical trauma.

The diagnosis is made by visualizing the lesion at the time of endoscopy; here, careful inspection of the hiatal hernia is required, as is familiarity with the appearance of the lesion (linear ulcers or erosions on the mucosal folds of a hiatal hernia at the diaphragmatic impression).

Management depends on the clinical setting. Acute bleeding can be treated endoscopically with standard hemostatic techniques [90]. Patients with iron deficiency from chronic bleeding can be treated with a proton pump inhibitor after iron repletion, which may help prevent recurrence of anemia [87]. Surgery to repair the hiatal hernia can be considered in patients with recurrent bleeding despite the above measures. (See "Overview of the treatment of bleeding peptic ulcers", section on 'Endoscopic therapy'.)

Aortoenteric fistulas — Aortoenteric fistula is a rare cause of acute UGIB and is most often iatrogenic. Because it is associated with a high mortality rate, it represents a true medical emergency. The third or fourth portion of the duodenum is the most common site for aortoenteric fistulas, followed by the jejunum and ileum [91,92]. (See "Aortoenteric fistula: Recognition and management".)

Most patients present with an initial "herald bleed" that is manifested by hematemesis and/or hematochezia; this may be followed up to several weeks later by massive bleeding and exsanguination. Intermittent bleeding can be seen if a blood clot temporarily seals the fistula. Other signs and symptoms may include abdominal or back pain, fever, and signs of sepsis. Infrequently, an abdominal mass is palpable or an

abdominal bruit is heard. (See "Aortoenteric fistula: Recognition and management", section on 'Clinical manifestations'.)

A high index of suspicion is needed to establish the diagnosis of an aortoenteric fistula. This disorder should be considered in all patients with massive or repetitive UGIB and a history of a thoracic or abdominal aortic aneurysm or a prosthetic vascular graft.

The diagnosis is typically made with imaging, such as CT or CT angiography. The reason that imaging is important diagnostically is that it has the potential to reveal the phlegmon that is most often present and lead to the formation of the aortoenteric fistula. It should be noted that angiography alone is not recommended because it often does not reveal the defect in the aorta/duodenum. Endoscopy is important primarily to exclude other, more common causes of acute UGIB, such as peptic ulcer disease. Endoscopy with an enteroscope or side-viewing endoscope may reveal a graft, an ulcer or erosion at the site of an adherent clot, or an extrinsic pulsatile mass in the distal duodenum (or rarely, the esophagus). Exploratory laparotomy may be considered in patients with a suspected aortoenteric fistula and severe ongoing bleeding. (See "Aortoenteric fistula: Recognition and management", section on 'Diagnosis'.)

The mortality rate of an untreated aortoenteric fistula that presents with upper GI hemorrhage is nearly 100 percent. Surgical repair of the aortic aneurysm and fistula is the standard treatment (though often difficult), regardless of the cause [92,93]. (See "Aortoenteric fistula: Recognition and management", section on 'Management'.)

Therapy of an aortoenteric fistula due to an infected graft consists of intravenous antibiotics and urgent surgical intervention [91,94]. (See "Aortoenteric fistula: Recognition and management", section on 'Management'.)

Other traumatic or iatrogenic causes — Other traumatic or iatrogenic causes of UGIB include foreign body ingestion, postsurgical anastomotic bleeding, postpolypectomy bleeding, and bleeding after sphincterotomy. (See "Post-endoscopic retrograde cholangiopancreatography (ERCP) bleeding".)

Foreign body ingestion may be seen in the setting of psychiatric disorders, dementia, or in patients with loose dentures. Plain radiographs of the neck, chest, and abdomen may reveal a radiopaque foreign body or signs of perforation. (See "Ingested foreign bodies and food impactions in adults".)

Patients with gastroenteric or enteroenteric anastomoses may develop bleeding from marginal ulcers. Causes of marginal ulcers include [95-98]:

- Poor tissue perfusion due to tension or ischemia at the anastomosis
- Presence of foreign material such as staples or nonabsorbable suture
- Excess exposure to acid
- NSAID use
- *H. pylori* infection
- Cigarette smoking

The diagnosis of a gastroenteric marginal ulcer is established by upper endoscopy, and initial medical treatment is with gastric acid suppression. Depending on the location, diagnosis of an enteroenteric marginal ulcer may require deep small bowel enteroscopy. (See "Late complications of bariatric surgical operations", section on 'Marginal ulcers' and "Overview of deep small bowel enteroscopy".)

Upper gastrointestinal tumors — Neoplasms of the upper gastrointestinal tract account for less than 3 percent of all cases of severe UGIB [99], but bleeding can be the initial manifestation of the tumor [100]. Bleeding may occur with both benign and malignant lesions. Bleeding can result from diffuse mucosal ulceration or from erosion into an underlying vessel. Virtually any tumor type may bleed, including adenocarcinomas, GI stromal tumors, lymphomas, and Kaposi sarcomas. While a less common cause of upper GI bleeding than many other tumors (eg, adenocarcinoma, GI stromal tumors), Kaposi sarcoma is particularly vascular in nature and should be considered in patients with HIV infection or in those who are immunosuppressed.

Endoscopic findings suggestive of gastric malignancy include irregular ulcer margins and an exophytic or fungating ulcerated mass (picture 10). Endoscopic biopsy, brushing, or needle aspiration for histologic or cytologic examination is performed for definitive diagnosis. Endoscopic ultrasound is useful for staging local disease, while CT scanning can be helpful for staging and detection of distant metastases. (See "Clinical features, diagnosis, and staging of gastric cancer" and "Epidemiology, classification, clinical presentation, prognostic features, and diagnostic work-up of gastrointestinal stromal tumors (GIST)".)

Patients with severe bleeding secondary to malignant upper GI tumors have a poor prognosis, and the majority of patients die within 12 months [99,100]. Surgical resection for cure or palliation is the treatment of choice. Medical therapy is most often palliative and consists of chemotherapy and/or radiation therapy. (See "Surgical management of invasive gastric cancer" and "Initial systemic therapy for locally advanced unresectable and metastatic esophageal and gastric cancer" and "Adjuvant and neoadjuvant treatment of gastric cancer".)

Endoscopic treatment for bleeding upper GI tumors includes standard techniques such as injection therapy, thermal contact probes (bipolar or heater probes), and APC. A more novel technique is the use of hemostatic nanopowder [1,100]. Preliminary data suggest that hemostatic nanopowder may be effective in some patients with bleeding due to GI tract cancer [101]. For all hemostatic techniques in patients with malignancy, control of active bleeding can be successful, but rebleeding is common, especially from nonhealing, malignant ulcers [102]. (See "Overview of the treatment of bleeding peptic ulcers", section on 'Hemostatic nanopowder'.)

Hemobilia — Hemobilia, or bleeding from the hepatobiliary tract, is a rare cause of acute UGIB. It should be considered in any patient with acute UGIB and a recent history of hepatic parenchymal or biliary tract instrumentation and/or injury, including percutaneous or transjugular liver biopsy [103-106], percutaneous transhepatic cholangiogram [107,108], cholecystectomy [109], endoscopic biliary biopsies or stenting, TIPS placement [110], angioembolization [111], or blunt or penetrating abdominal trauma. Other causes of hemobilia include gallstones, cholecystitis [112], hepatic or bile duct tumors, intrahepatic stents [113], hepatic artery aneurysms [114], and hepatic abscesses [114].

The classic triad of hemobilia (biliary colic, obstructive jaundice, and occult or acute GI bleeding [115]) is uncommonly present. Obstructive jaundice, with or without biliary sepsis, may occur if blood clots within the biliary system.

The diagnosis of hemobilia is often overlooked if the papilla is not carefully examined endoscopically. A side-viewing duodenoscope is helpful for visualizing the ampulla and may be useful for performing diagnostic endoscopic retrograde cholangiopancreatography (ERCP) in this setting [116]. Cross-sectional

imaging (with CT or magnetic resonance imaging, including magnetic resonance cholangiopancreatography [MRCP]) is often helpful in patients with hemobilia and should be considered early in the course of the evaluation. Technetium-tagged red blood cell scan or selective hepatic artery angiography may reveal the source of hemobilia [117]. (See "Evaluation of suspected small bowel bleeding (formerly obscure gastrointestinal bleeding)", section on 'Radiographic imaging'.)

Treatment is directed at the primary cause of bleeding, such as embolization or surgical resection of a hepatic tumor [118]. In the case of bleeding following liver biopsy [105,119], laparoscopic cholecystectomy [120], or percutaneous transhepatic cholangiogram [121], arterial embolization is often employed and is typically effective. (See "Angiographic control of nonvariceal gastrointestinal bleeding in adults", section on 'Embolization'.)

Hemosuccus pancreaticus — Hemosuccus pancreaticus, or bleeding from the pancreatic duct, is another rare cause of UGIB. It is most often found in patients with chronic pancreatitis, pancreatic pseudocysts, or pancreatic tumors. Bleeding occurs when a pseudocyst or tumor erodes into a vessel, forming a direct communication between the pancreatic duct and vessel. The vessel involved is often a splenic artery pseudoaneurysm [122]. Hemosuccus pancreaticus may also be found after therapeutic endoscopy of the pancreas or pancreatic duct, including pancreatic stone removal, pancreatic duct sphincterotomy, pseudocyst drainage, or pancreatic duct stenting. Bleeding is often aggressive and may be life-threatening.

Hemosuccus pancreaticus should be suspected clinically when UGIB occurs in one of the above settings in which pancreatic injury is present. The diagnosis is usually best confirmed with cross-sectional imaging (ie, abdominal CT scanning and/or MRCP, although ERCP or intraoperative exploration may also be used) [123-125]. Cross-sectional imaging is usually performed first because it is the least invasive modality.

Mesenteric arteriography with coil embolization can control acute bleeding and is usually the preferred treatment [123,125]. If bleeding persists or is massive, treatment is with pancreaticoduodenectomy and ligation of the bleeding vessel, which definitively prevents rebleeding [126,127]. (See "Angiographic control of nonvariceal gastrointestinal bleeding in adults", section on 'Embolization'.)

SOCIETY GUIDELINE LINKS

Links to society and government-sponsored guidelines from selected countries and regions around the world are provided separately. (See "Society guideline links: Gastrointestinal bleeding in adults".)

INFORMATION FOR PATIENTS

UpToDate offers two types of patient education materials, "The Basics" and "Beyond the Basics." The Basics patient education pieces are written in plain language, at the 5th to 6th grade reading level, and they answer the four or five key questions a patient might have about a given condition. These articles are best for patients who want a general overview and who prefer short, easy-to-read materials. Beyond the Basics patient education pieces are longer, more sophisticated, and more detailed. These articles are written at the 10th to 12th grade reading level and are best for patients who want in-depth information and are comfortable with some medical jargon.

Here are the patient education articles that are relevant to this topic. We encourage you to print or e-mail these topics to your patients. (You can also locate patient education articles on a variety of subjects by searching on "patient info" and the keyword(s) of interest.)

- Basics topics (see "Patient education: Upper endoscopy (The Basics)" and "Patient education: Peptic ulcers (The Basics)" and "Patient education: Acid reflux (gastroesophageal reflux disease) in adults (The Basics)")
- Beyond the Basics topics (see "Patient education: Upper endoscopy (Beyond the Basics)" and "Patient education: Peptic ulcer disease (Beyond the Basics)" and "Patient education: Acid reflux (gastroesophageal reflux disease) in adults (Beyond the Basics)")

SUMMARY

- Upper gastrointestinal bleeding (UGIB) is a common medical condition that results in high patient morbidity and medical care costs, with an annual incidence in the Unites States of approximately 65 per 100,000 adults. (See 'Epidemiology' above.)
- The causes of UGIB can be classified into several broad categories based on anatomic and pathophysiologic factors (table 1). The most common causes of UGIB include peptic ulcer disease, esophagogastric varices, and erosive esophagitis. (See 'Differential diagnosis' above and 'Specific causes' above.)
- Most causes of UGIB are diagnosed endoscopically, and in many patients, endoscopic therapy is the treatment of choice. (See "Approach to acute upper gastrointestinal bleeding in adults".)

ACKNOWLEDGMENT

The author and UpToDate would like to thank Drs. Rome Jutabha and Dennis Jensen, who contributed to earlier versions of this topic review.

Use of UpToDate is subject to the Subscription and License Agreement.

REFERENCES

1. Wuerth BA, Rockey DC. Changing Epidemiology of Upper Gastrointestinal Hemorrhage in the Last Decade: A Nationwide Analysis. Dig Dis Sci 2018; 63:1286.
2. Longstreth GF. Epidemiology of hospitalization for acute upper gastrointestinal hemorrhage: a population-based study. Am J Gastroenterol 1995; 90:206.
3. Lanas A, Perez-Aisa MA, Feu F, et al. A nationwide study of mortality associated with hospital admission due to severe gastrointestinal events and those associated with nonsteroidal antiinflammatory drug use. Am J Gastroenterol 2005; 100:1685.

4. Boonpongmanee S, Fleischer DE, Pezzullo JC, et al. The frequency of peptic ulcer as a cause of upper-GI bleeding is exaggerated. Gastrointest Endosc 2004; 59:788.

5. Enestvedt BK, Gralnek IM, Mattek N, et al. An evaluation of endoscopic indications and findings related to nonvariceal upper-GI hemorrhage in a large multicenter consortium. Gastrointest Endosc 2008; 67:422.

6. Balderas V, Bhore R, Lara LF, et al. The hematocrit level in upper gastrointestinal hemorrhage: safety of endoscopy and outcomes. Am J Med 2011; 124:970.

7. Loperfido S, Baldo V, Piovesana E, et al. Changing trends in acute upper-GI bleeding: a population-based study. Gastrointest Endosc 2009; 70:212.

8. Acosta RD, Wong RK. Differential diagnosis of upper gastrointestinal bleeding proximal to the ligament of Trietz. Gastrointest Endosc Clin N Am 2011; 21:555.

9. Wollenman CS, Chason R, Reisch JS, Rockey DC. Impact of ethnicity in upper gastrointestinal hemorrhage. J Clin Gastroenterol 2014; 48:343.

10. Lee YT, Walmsley RS, Leong RW, Sung JJ. Dieulafoy's lesion. Gastrointest Endosc 2003; 58:236.

11. de Melo SW Jr, Bhore R, Rockey DC. Clinical judgment does not circumvent the need for diagnostic endoscopy in upper gastrointestinal hemorrhage. J Investig Med 2013; 61:1146.

12. Gralnek IM, Barkun AN, Bardou M. Management of acute bleeding from a peptic ulcer. N Engl J Med 2008; 359:928.

13. Laine L, Jensen DM. Management of patients with ulcer bleeding. Am J Gastroenterol 2012; 107:345.

14. Hunt RH, Malfertheiner P, Yeomans ND, et al. Critical issues in the pathophysiology and management of peptic ulcer disease. Eur J Gastroenterol Hepatol 1995; 7:685.

15. Hallas J, Lauritsen J, Villadsen HD, Gram LF. Nonsteroidal anti-inflammatory drugs and upper gastrointestinal bleeding, identifying high-risk groups by excess risk estimates. Scand J Gastroenterol 1995; 30:438.

16. Graham DY, Hepps KS, Ramirez FC, et al. Treatment of Helicobacter pylori reduces the rate of rebleeding in peptic ulcer disease. Scand J Gastroenterol 1993; 28:939.

17. Tytgat GN. Peptic ulcer and Helicobacter pylori: eradication and relapse. Scand J Gastroenterol Suppl 1995; 210:70.

18. Rokkas T, Karameris A, Mavrogeorgis A, et al. Eradication of Helicobacter pylori reduces the possibility of rebleeding in peptic ulcer disease. Gastrointest Endosc 1995; 41:1.

19. Bayerdörffer E, Neubauer A, Rudolph B, et al. Regression of primary gastric lymphoma of mucosa-associated lymphoid tissue type after cure of Helicobacter pylori infection. MALT Lymphoma Study Group. Lancet 1995; 345:1591.

20. Nakamura S, Yao T, Aoyagi K, et al. Helicobacter pylori and primary gastric lymphoma. A histopathologic and immunohistochemical analysis of 237 patients. Cancer 1997; 79:3.

21. Parsonnet J, Hansen S, Rodriguez L, et al. Helicobacter pylori infection and gastric lymphoma. N Engl J Med 1994; 330:1267.

22. Pajares JM. H. pylori infection: its role in chronic gastritis, carcinoma and peptic ulcer. Hepatogastroenterology 1995; 42:827.

23. Shibata T, Imoto I, Ohuchi Y, et al. Helicobacter pylori infection in patients with gastric carcinoma in biopsy and surgical resection specimens. Cancer 1996; 77:1044.

24. Lanas A, Wu P, Medin J, Mills EJ. Low doses of acetylsalicylic acid increase risk of gastrointestinal bleeding in a meta-analysis. Clin Gastroenterol Hepatol 2011; 9:762.

25. De Berardis G, Lucisano G, D'Ettorre A, et al. Association of aspirin use with major bleeding in patients with and without diabetes. JAMA 2012; 307:2286.

26. Hansen JM, Hallas J, Lauritsen JM, Bytzer P. Non-steroidal anti-inflammatory drugs and ulcer complications: a risk factor analysis for clinical decision-making. Scand J Gastroenterol 1996; 31:126.

27. Koch M, Dezi A, Ferrario F, Capurso I. Prevention of nonsteroidal anti-inflammatory drug-induced gastrointestinal mucosal injury. A meta-analysis of randomized controlled clinical trials. Arch Intern Med 1996; 156:2321.

28. Smalley WE, Ray WA, Daugherty JR, Griffin MR. Nonsteroidal anti-inflammatory drugs and the incidence of hospitalizations for peptic ulcer disease in elderly persons. Am J Epidemiol 1995; 141:539.

29. Lanas AI, Remacha B, Esteva F, Sáinz R. Risk factors associated with refractory peptic ulcers. Gastroenterology 1995; 109:1124.

30. Terdiman JP, Ostroff JW. Gastrointestinal bleeding in the hospitalized patient: a case-control study to assess risk factors, causes, and outcome. Am J Med 1998; 104:349.

31. Sung JJ. Management of nonsteroidal anti-inflammatory drug-related peptic ulcer bleeding. Am J Med 2001; 110:29S.

32. Sung JJ, Tsoi KK, Ma TK, et al. Causes of mortality in patients with peptic ulcer bleeding: a prospective cohort study of 10,428 cases. Am J Gastroenterol 2010; 105:84.

33. Chason RD, Reisch JS, Rockey DC. More favorable outcomes with peptic ulcer bleeding due to Helicobacter pylori. Am J Med 2013; 126:811.

34. Guntipalli P, Chason R, Elliott A, Rockey DC. Upper gastrointestinal bleeding caused by severe esophagitis: a unique clinical syndrome. Dig Dis Sci 2014; 59:2997.

35. Yip R, Limburg PJ, Ahlquist DA, et al. Pervasive occult gastrointestinal bleeding in an Alaska native population with prevalent iron deficiency. Role of Helicobacter pylori gastritis. JAMA 1997; 277:1135.

36. Pang SH, Leung WK, Graham DY. Ulcers and gastritis. Endoscopy 2008; 40:136.

37. Lyles T, Elliott A, Rockey DC. A risk scoring system to predict in-hospital mortality in patients with cirrhosis presenting with upper gastrointestinal bleeding. J Clin Gastroenterol 2014; 48:712.

38. Garcia-Tsao G, Sanyal AJ, Grace ND, et al. Prevention and management of gastroesophageal varices and variceal hemorrhage in cirrhosis. Hepatology 2007; 46:922.

39. de Souza AR, La Mura V, Reverter E, et al. Patients whose first episode of bleeding occurs while taking a β-blocker have high long-term risks of rebleeding and death. Clin Gastroenterol Hepatol 2012; 10:670.

40. North Italian Endoscopic Club for the Study and Treatment of Esophageal Varices. Prediction of the first variceal hemorrhage in patients with cirrhosis of the liver and esophageal varices. A prospective multicenter study. N Engl J Med 1988; 319:983.

41. Kim T, Shijo H, Kokawa H, et al. Risk factors for hemorrhage from gastric fundal varices. Hepatology 1997; 25:307.

42. García-Pagán JC, Caca K, Bureau C, et al. Early use of TIPS in patients with cirrhosis and variceal bleeding. N Engl J Med 2010; 362:2370.

43. Caldwell S. Gastric varices: is there a role for endoscopic cyanoacrylates, or are we entering the BRTO era? Am J Gastroenterol 2012; 107:1784.

44. Rockey DC. Occult and obscure gastrointestinal bleeding: causes and clinical management. Nat Rev Gastroenterol Hepatol 2010; 7:265.

45. Gunnlaugsson O. Angiodysplasia of the stomach and duodenum. Gastrointest Endosc 1985; 31:251.

46. Clouse RE, Costigan DJ, Mills BA, Zuckerman GR. Angiodysplasia as a cause of upper gastrointestinal bleeding. Arch Intern Med 1985; 145:458.

47. Moretó M, Figa M, Ojembarrena E, Zaballa M. Vascular malformations of the stomach and duodenum: an endoscopic classification. Endoscopy 1986; 18:227.

48. Pollack R, Lipsky H, Goldberg RI. Duodenal Dieulafoy's lesion. Gastrointest Endosc 1993; 39:820.

49. Anireddy D, Timberlake G, Seibert D. Dieulafoy's lesion of the esophagus. Gastrointest Endosc 1993; 39:604.

50. Choudari CP, Palmer KR. Dieulafoy's lesion of the duodenum; successful endoscopic therapy. Endoscopy 1993; 25:371.

51. Lara LF, Sreenarasimhaiah J, Tang SJ, et al. Dieulafoy lesions of the GI tract: localization and therapeutic outcomes. Dig Dis Sci 2010; 55:3436.

52. Kaufman Z, Liverant S, Shiptz B, Dinbar A. Massive gastrointestinal bleeding caused by Dieulafoy's lesion. Am Surg 1995; 61:453.

53. Squillace SJ, Johnson DA, Sanowski RA. The endosonographic appearance of a Dieulafoy's lesion. Am J Gastroenterol 1994; 89:276.

54. Chen YY, Su WW, Soon MS, Yen HH. Delayed fatal hemorrhage after endoscopic band ligation for gastric Dieulafoy's lesion. Gastrointest Endosc 2005; 62:630.

55. Dulic-Lakovic E, Dulic M, Hubner D, et al. Bleeding Dieulafoy lesions of the small bowel: a systematic study on the epidemiology and efficacy of enteroscopic treatment. Gastrointest Endosc 2011; 74:573.

56. Yamaguchi Y, Yamato T, Katsumi N, et al. Short-term and long-term benefits of endoscopic hemoclip application for Dieulafoy's lesion in the upper GI tract. Gastrointest Endosc 2003; 57:653.

57. Matsui S, Kamisako T, Kudo M, Inoue R. Endoscopic band ligation for control of nonvariceal upper GI hemorrhage: comparison with bipolar electrocoagulation. Gastrointest Endosc 2002; 55:214.

58. Iacopini F, Petruzziello L, Marchese M, et al. Hemostasis of Dieulafoy's lesions by argon plasma coagulation (with video). Gastrointest Endosc 2007; 66:20.

59. Mumtaz R, Shaukat M, Ramirez FC. Outcomes of endoscopic treatment of gastroduodenal Dieulafoy's lesion with rubber band ligation and thermal/injection therapy. J Clin Gastroenterol 2003; 36:310.

60. Nadal E, Burra P, Senzolo M. Cyanoacrylate injection to treat recurrent bleeding from Dieulafoy's lesion. Gastrointest Endosc 2013; 78:964.

61. D'Imperio N, Papadia C, Baroncini D, et al. N-butyl-2-cyanoacrylate in the endoscopic treatment of Dieulafoy ulcer. Endoscopy 1995; 27:216.

62. Barker KB, Arnold HL, Fillman EP, et al. Safety of band ligator use in the small bowel and the colon. Gastrointest Endosc 2005; 62:224.

63. Jaspersen D. Dieulafoy's disease controlled by Doppler ultrasound endoscopic treatment. Gut 1993; 34:857.

64. Payen JL, Calès P, Voigt JJ, et al. Severe portal hypertensive gastropathy and antral vascular ectasia are distinct entities in patients with cirrhosis. Gastroenterology 1995; 108:138.

65. Ito M, Uchida Y, Kamano S, et al. Clinical comparisons between two subsets of gastric antral vascular ectasia. Gastrointest Endosc 2001; 53:764.

66. Dulai GS, Jensen DM, Kovacs TO, et al. Endoscopic treatment outcomes in watermelon stomach patients with and without portal hypertension. Endoscopy 2004; 36:68.

67. Barnard GF, Colby JM, Saltzman JR, et al. Endoscopic ultrasound appearance of watermelon stomach. Abdom Imaging 1995; 20:26.

68. McGorisk T, Krishnan K, Keefer L, Komanduri S. Radiofrequency ablation for refractory gastric antral vascular ectasia (with video). Gastrointest Endosc 2013; 78:584.

69. Spahr L, Villeneuve JP, Dufresne MP, et al. Gastric antral vascular ectasia in cirrhotic patients: absence of relation with portal hypertension. Gut 1999; 44:739.

70. Kamath PS, Lacerda M, Ahlquist DA, et al. Gastric mucosal responses to intrahepatic portosystemic shunting in patients with cirrhosis. Gastroenterology 2000; 118:905.

71. Manning RJ. Estrogen/progesterone treatment of diffuse antral vascular ectasia. Am J Gastroenterol 1995; 90:154.

72. Weaver DH, Maxwell JG, Castleton KB. Mallory-Weiss syndrome. Am J Surg 1969; 118:887.

73. Watts HD, Admirand WH. Mallory-Weiss syndrome. A reappraisal. JAMA 1974; 230:1674.

74. Michel L, Serrano A, Malt RA. Mallory-Weiss syndrome. Evolution of diagnostic and therapeutic patterns over two decades. Ann Surg 1980; 192:716.

75. Skok P. Fatal hemorrhage from a giant Mallory-Weiss tear. Endoscopy 2003; 35:635.

76. Santoro MJ, Chen YK, Collen MJ. Polyethylene glycol electrolyte lavage solution-induced Mallory-Weiss tears. Am J Gastroenterol 1993; 88:1292.

77. Fishman ML, Thirlwell MP, Daly DS. Mallory-Weiss tear. A complication of cancer chemotherapy. Cancer 1983; 52:2031.

78. Penston JG, Boyd EJ, Wormsley KG. Mallory-Weiss tears occurring during endoscopy: a report of seven cases. Endoscopy 1992; 24:262.

79. Shimoda R, Iwakiri R, Sakata H, et al. Endoscopic hemostasis with metallic hemoclips for iatrogenic Mallory-Weiss tear caused by endoscopic examination. Dig Endosc 2009; 21:20.

80. Knauer CM. Mallory-Weiss syndrome. Characterization of 75 Mallory-weiss lacerations in 528 patients with upper gastrointestinal hemorrhage. Gastroenterology 1976; 71:5.

81. Kovacs TO, Jensen DM. Endoscopic diagnosis and treatment of bleeding Mallory-Weiss tears. Gastrointest Endosc Clin North Am 1991; 1:387.

82. Cameron AJ. Incidence of iron deficiency anemia in patients with large diaphragmatic hernia. A controlled study. Mayo Clin Proc 1976; 51:767.

83. Cameron AJ, Higgins JA. Linear gastric erosion. A lesion associated with large diaphragmatic hernia and chronic blood loss anemia. Gastroenterology 1986; 91:338.

84. Weston AP. Hiatal hernia with cameron ulcers and erosions. Gastrointest Endosc Clin N Am 1996; 6:671.

85. Ruhl CE, Everhart JE. Relationship of iron-deficiency anemia with esophagitis and hiatal hernia: hospital findings from a prospective, population-based study. Am J Gastroenterol 2001; 96:322.

86. Moskovitz M, Fadden R, Min T, et al. Large hiatal hernias, anemia, and linear gastric erosion: studies of etiology and medical therapy. Am J Gastroenterol 1992; 87:622.

87. Panzuto F, Di Giulio E, Capurso G, et al. Large hiatal hernia in patients with iron deficiency anaemia: a prospective study on prevalence and treatment. Aliment Pharmacol Ther 2004; 19:663.

88. Kapadia S, Jagroop S, Kumar A. Cameron ulcers: an atypical source for a massive upper gastrointestinal bleed. World J Gastroenterol 2012; 18:4959.

89. Zullo A, Manta R, De Francesco V, et al. Cameron lesions: A still overlooked diagnosis. Case report and systematic review of literature. Clin Res Hepatol Gastroenterol 2018; 42:604.

90. Lin CC, Chen TH, Ho WC, Chen TY. Endoscopic treatment of a Cameron lesion presenting as life-threatening gastrointestinal hemorrhage. J Clin Gastroenterol 2001; 33:423.

91. Antinori CH, Andrew CT, Santaspirt JS, et al. The many faces of aortoenteric fistulas. Am Surg 1996; 62:344.

92. Cendan JC, Thomas JB 4th, Seeger JM. Twenty-one cases of aortoenteric fistula: lessons for the general surgeon. Am Surg 2004; 70:583.

93. Kakkos SK, Bicknell CD, Tsolakis IA, et al. Editor's Choice - Management of Secondary Aorto-enteric and Other Abdominal Arterio-enteric Fistulas: A Review and Pooled Data Analysis. Eur J Vasc Endovasc Surg 2016; 52:770.

94. Voorhoeve R, Moll FL, de Letter JA, et al. Primary aortoenteric fistula: report of eight new cases and review of the literature. Ann Vasc Surg 1996; 10:40.

95. Sapala JA, Wood MH, Sapala MA, Flake TM Jr. Marginal ulcer after gastric bypass: a prospective 3-year study of 173 patients. Obes Surg 1998; 8:505.

96. Dallal RM, Bailey LA. Ulcer disease after gastric bypass surgery. Surg Obes Relat Dis 2006; 2:455.

97. Sataloff DM, Lieber CP, Seinige UL. Strictures following gastric stapling for morbid obesity. Results of endoscopic dilatation. Am Surg 1990; 56:167.

98. Rasmussen JJ, Fuller W, Ali MR. Marginal ulceration after laparoscopic gastric bypass: an analysis of predisposing factors in 260 patients. Surg Endosc 2007; 21:1090.

99. Savides TJ, Jensen DM, Cohen J, et al. Severe upper gastrointestinal tumor bleeding: endoscopic findings, treatment, and outcome. Endoscopy 1996; 28:244.

100. Schatz RA, Rockey DC. Gastrointestinal Bleeding Due to Gastrointestinal Tract Malignancy: Natural History, Management, and Outcomes. Dig Dis Sci 2017; 62:491.

101. Sheibani S, Kim JJ, Chen B, et al. Natural history of acute upper GI bleeding due to tumours: short-term success and long-term recurrence with or without endoscopic therapy. Aliment Pharmacol Ther 2013; 38:144.

102. Chen YI, Barkun AN, Soulellis C, et al. Use of the endoscopically applied hemostatic powder TC-325 in cancer-related upper GI hemorrhage: preliminary experience (with video). Gastrointest Endosc 2012; 75:1278.

103. Counihan TC, Islam S, Swanson RS. Acute cholecystitis resulting from hemobilia after tru-cut biopsy: a case report and brief review of the literature. Am Surg 1996; 62:757.

104. Jabbour N, Reyes J, Zajko A, et al. Arterioportal fistula following liver biopsy. Three cases occurring in liver transplant recipients. Dig Dis Sci 1995; 40:1041.

105. Murata K, Oohashi Y, Takase K, et al. A case of hemobilia after percutaneous liver biopsy treated by transcatheter arterial embolization with Histoacryl. Am J Gastroenterol 1996; 91:160.

106. Van Os EC, Petersen BT. Pancreatitis secondary to percutaneous liver biopsy-associated hemobilia. Am J Gastroenterol 1996; 91:577.

107. Goodwin SC, Stainken BF, McNamara TO, Yoon HC. Prevention of significant hemobilia during placement of transhepatic biliary drainage catheters: technique modification and initial results. J Vasc Interv Radiol 1995; 6:229.

108. Savader SJ, Trerotola SO, Merine DS, et al. Hemobilia after percutaneous transhepatic biliary drainage: treatment with transcatheter embolotherapy. J Vasc Interv Radiol 1992; 3:345.

109. Yelle JD, Fairfull-Smith R, Rasuli P, Lorimer JW. Hemobilia complicating elective laparoscopic cholecystectomy: a case report. Can J Surg 1996; 39:240.

110. Menzel J, Vestring T, Foerster EC, et al. Arterio-biliary fistula after transjugular intrahepatic portosystemic shunt: a life-threatening complication of the new technique for therapy of portal hypertension. Z Gastroenterol 1995; 33:255.

111. Moreno RD, Harris M, Bryk HB, et al. Late presentation of a hepatic pseudoaneurysm with hemobilia after angioembolization for blunt hepatic trauma. J Trauma 2007; 62:1048.

112. Gonzalez-Ortiz DI, Toro DH, Vega W. Hemobilia: a rare presentation of acute cholecystitis. Clin Gastroenterol Hepatol 2008; 6:e36.

113. Monroe PS, Deeter WT, Rizk P. Delayed hemobilia secondary to expandable metal stent. Gastrointest Endosc 1993; 39:190.

114. Liou TC, Ling CC, Pang KK. Liver abscess concomitant with hemobilia due to rupture of hepatic artery aneurysm: a case report. Hepatogastroenterology 1996; 43:241.

115. Bloechle C, Izbicki JR, Rashed MY, et al. Hemobilia: presentation, diagnosis, and management. Am J Gastroenterol 1994; 89:1537.

116. Sherman S, Jamidar P, Shaked A, et al. Biliary tract complications after orthotopic liver transplantation. Endoscopic approach to diagnosis and therapy. Transplantation 1995; 60:467.

117. Spieth ME, Hou CC, Ewing PD, et al. Hemobilia presenting as intermittent gastrointestinal hemorrhage with sincalide confirmation. A case report. Clin Nucl Med 1995; 20:391.

118. Kotoh K, Satoh M, Kyoda S, et al. Successful control of hemobilia secondary to metastatic liver cancer with transcatheter arterial embolization. Am J Gastroenterol 1991; 86:1642.

119. Grieco A, Bianco A, Pieri S, et al. Massive haemobilia after percutaneous liver biopsy in a patient with POEMS syndrome successfully treated by arterial embolization. Eur J Gastroenterol Hepatol 1996;

8:595.

120. Rivitz SM, Waltman AC, Kelsey PB. Embolization of an hepatic artery pseudoaneurysm following laparoscopic cholecystectomy. Cardiovasc Intervent Radiol 1996; 19:43.

121. Smith TP, McDermott VG, Ayoub DM, et al. Percutaneous transhepatic liver biopsy with tract embolization. Radiology 1996; 198:769.

122. Anil Kothari R, Leelakrishnan V, Krishnan M. Hemosuccus pancreaticus: a rare cause of gastrointestinal bleeding. Ann Gastroenterol 2013; 26:175.

123. Suter M, Doenz F, Chapuis G, et al. Haemorrhage into the pancreatic duct (Hemosuccus pancreaticus): recognition and management. Eur J Surg 1995; 161:887.

124. Risti B, Marincek B, Jost R, et al. Hemosuccus pancreaticus as a source of obscure upper gastrointestinal bleeding: three cases and literature review. Am J Gastroenterol 1995; 90:1878.

125. Lermite E, Regenet N, Tuech JJ, et al. Diagnosis and treatment of hemosuccus pancreaticus: development of endovascular management. Pancreas 2007; 34:229.

126. Arnaud JP, Bergamaschi R, Serra-Maudet V, Casa C. Pancreatoduodenectomy for hemosuccus pancreaticus in silent chronic pancreatitis. Arch Surg 1994; 129:333.

127. Wagner WH, Cossman DV, Treiman RL, et al. Hemosuccus pancreaticus from intraductal rupture of a primary splenic artery aneurysm. J Vasc Surg 1994; 19:158.

Topic 2644 Version 20.0

GRAPHICS

Disorders that cause upper GI bleeding in adults

Cause	Bleeding manifestations	Associated signs and symptoms	Associated conditions or risk factors	Endoscopic findings*
Ulcerative or erosive				
Duodenal and/or gastric ulcer	Hematemesis Melena Hematochezia (indicates brisk bleeding) Occult blood loss	Upper abdominal pain Pain associated with eating (worse when eating suggests gastric ulcer, improvement with eating suggests duodenal ulcer) Dyspepsia¶	Infections: ▪ *Helicobacter pylori* ▪ CMV ▪ HSV NSAIDs Stress ulcer (eg, in patients who are critically ill) Excess gastric acid production (ZES) Idiopathic	Ulcer with smooth, regular, rounded edges; ulcer base often filled with exudate Examination of the ulcer may reveal: ▪ Active bleeding or oozing ▪ Nonbleeding visible vessel ▪ Adherent clot ▪ Flat pigmented spot ▪ Clean ulcer base
Esophagitis	Hematemesis Melena Occult blood loss	Dysphagia/odynophagia Retrosternal pain Food impaction	Gastroesophageal reflux disease Medications that may cause "pill esophagitis": ▪ Erythromycin ▪ Tetracycline ▪ Doxycycline ▪ Clindamycin ▪ Trimethoprim-sulfamethoxazole ▪ NSAIDs ▪ Oral bisphosphonates ▪ Potassium chloride ▪ Quinidine ▪ Iron supplements Infections: ▪ HSV ▪ CMV ▪ *Candida albicans* ▪ HIV	Erythema, mucosal breaks/erosions, exudative lesions, superficial or deep ulcers, stenosis, scarring Peptic esophagitis: The ulcerations are usually irregularly shaped or linear, multiple, and distal; may be accompanied by Barrett's esophagus Pill-induced: Ulcerations are usually singular and deep, occurring at points of stasis (especially near the carina), with sparing of the distal esophagus Infectious esophagitis: ▪ HSV – Discrete, superficial ulcers, with well-demarcated borders that tend to involve the upper or mid-esophagus; vesicles may be seen ▪ CMV – Ulcers range from small and shallow to large (>1 cm) and deep; most patients have multiple lesions ▪ *Candida* – Diffuse white plaques

				▪ HIV – Tends to involve the mid to distal esophagus, ulcers may be shallow or deep, and may be large
Gastritis/gastropathy Duodenitis/duodenopathy	Occult blood loss Hematemesis Melena	Dyspepsia[¶]	Risk factors: ▪ *H. pylori* ▪ NSAIDs ▪ Excessive alcohol consumption ▪ Radiation injury ▪ Physiologic stress ▪ Weight loss surgery ▪ Bile reflux Risk factors for bleeding: ▪ Anticoagulant use	Erythematous mucosa Superficial erosions Nodularity Diffuse oozing
Complications of portal hypertension				
Esophagogastric varices	Hematemesis Melena Hematochezia (indicates brisk bleeding)	Stigmata of chronic liver disease[Δ], in particular, signs of portal hypertension (splenomegaly, ascites, thrombocytopenia)	Portal hypertension from: ▪ Cirrhosis ▪ Portal vein thrombosis ▪ Noncirrhotic portal hypertension	Vascular structures that protrude into the esophageal and/or gastric lumen Findings associated with an increased risk of hemorrhage: ▪ Longitudinal red streaks on the varices (red wale marks) ▪ Cherry-colored spots that are flat and overlie varices ▪ Raised, discrete red spots (hematocystic spots) Esophageal varices: ▪ F1: Small, straight varices ▪ F2: Enlarged, tortuous varices that occupy less than one-third of the lumen ▪ F3: Large, coil-shaped varices that occupy more than one-third of the lumen Gastric varices: ▪ GOV1: Gastroesophageal varices along the lesser curvature of the stomach ▪ GOV2: Gastroesophageal varices along the greater curvature of the stomach ▪ IGV1: Isolated gastric varices in

				the fundus ▪ IGV2: Isolated gastric varices at other loci in the stomach
Ectopic varices	Hematemesis Melena Hematochezia (indicates brisk bleeding)	Stigmata of chronic liver disease[Δ], in particular, signs of portal hypertension (splenomegaly, ascites, thrombocytopenia)	Portal hypertension from: ▪ Cirrhosis ▪ Portal vein thrombosis ▪ Noncirrhotic portal hypertension	Vascular structures that protrude into areas of the gastrointestinal tract lumen other than the esophagus or stomach (eg, small bowel, rectum)
Portal hypertensive gastropathy	Occult blood loss Hematemesis Melena Hematochezia (indicates brisk bleeding)	Stigmata of chronic liver disease[Δ], in particular, signs of portal hypertension (splenomegaly, ascites, thrombocytopenia)	Portal hypertension from: ▪ Cirrhosis ▪ Portal vein thrombosis ▪ Noncirrhotic portal hypertension	Mosaic-like pattern that gives the gastric mucosa a "snakeskin" appearance Mucosal changes are usually most evident in the fundus and body; in more severe cases, oozing, bleeding, subepithelial hemorrhages, and increased vascularity similar to angiomas are evident, often involving the gastric fundus, gastric body, and antrum
Vascular lesions				
Angiodysplasia	Hematemesis Melena Hematochezia Occult blood loss May have brisk bleeding	Cutaneous angiodysplasia in patients with hereditary hemorrhagic telangiectasia (Osler-Weber-Rendu syndrome)	End-stage renal disease Aortic stenosis Left ventricular assist device Hereditary hemorrhagic telangiectasia von Willebrand disease Radiation therapy Idiopathic	Small (5 to 10 mm), flat, cherry-red lesions, often with a fern-like pattern of arborizing, ectatic blood vessels radiating from a central vessel
Dieulafoy's lesion	Hematemesis Melena Hematochezia (indicates brisk bleeding; bleeding is often particularly brisk)		Etiology unknown Bleeding may be associated with NSAIDs, cardiovascular disease, hypertension, chronic kidney disease, diabetes, or alcohol abuse	Usually located in the proximal stomach (within 6 cm of the esophagogastric junction) along the lesser curvature (although can be found anywhere in the GI tract) May have active arterial spurting from the mucosa without an associated ulcer or mass If the bleeding has stopped, there may be a raised nipple or visible vessel without an associated ulcer Endoscopic ultrasound may help confirm the diagnosis
Gastric antral vascular ectasia (GAVE)	Hematemesis Melena	In patients with cirrhosis, there may be stigmata of	Idiopathic	Longitudinal rows of flat, reddish stripes

	Hematochezia (indicates brisk bleeding) Occult blood loss	chronic liver disease[Δ], in particular, signs of portal hypertension (splenomegaly, ascites, thrombocytopenia)	Cirrhosis with portal hypertension Renal disease/transplantation Diabetes mellitus Systemic sclerosis (scleroderma) Bone marrow transplantation	radiating from the pylorus into the antrum that resemble the stripes on a watermelon
Blue rubber bleb nevus syndrome (Bean syndrome)	Hematemesis Melena Hematochezia (indicates brisk bleeding) Occult blood loss	Venous malformations and hemangiomas of any organ, including: ▪ Skin ▪ Central nervous system ▪ Liver ▪ Muscles ▪ Lymphatics Intussusception		Blue or purple nodules, round or multilobular; may occur anywhere in the gastrointestinal tract
Traumatic or iatrogenic				
Mallory-Weiss syndrome	Hematemesis following an increase in intra-abdominal pressure Melena Hematochezia (indicates brisk bleeding)	Epigastric pain Back pain	Vomiting/retching (often related to alcohol consumption) Straining at stool or lifting Coughing Seizures Blunt abdominal trauma Hiatal hernia may increase the risk of developing a tear	Tear in the esophagogastric junction Usually singular and longitudinal, but may be multiple Visualization may require retroflexion of the gastroscope in the cardia of the stomach The tear may be covered by an adherent clot
Foreign body ingestion	Hematemesis Melena Hematochezia (indicates brisk bleeding) Occult blood loss	Dysphagia Odynophagia Neck or abdominal pain Choking Hypersalivation Retrosternal fullness	Psychiatric disorders Altered mental status (toxin induced, dementia, etc.) Loose dentures	Visualization of the foreign body endoscopically (plain radiographs of the neck, chest, and abdomen may reveal a radiopaque foreign body or signs of perforation)
Post-surgical anastomotic bleeding ("marginal ulcers")	Occult blood loss Hematemesis Melena Hematochezia (indicates brisk bleeding)	Epigastric pain Nausea	Billroth II surgery Gastric bypass surgery NSAID use *H. pylori* infection Smoking	Ulceration/friable mucosa at an anastomotic site
Post-polypectomy/endoscopic resection/endoscopic sphincterotomy	Hematemesis Melena Hematochezia (indicates brisk bleeding)	Past history of instrumentation (may be as long as three weeks prior to presentation)	Large lesions	Bleeding at resection site; ulceration at the site may be seen
Cameron lesions	Occult blood loss Hematemesis Melena Hematochezia (indicates brisk bleeding)		Hiatal hernia Reflux esophagitis	Linear ulcers or erosions on the mucosal folds of a hiatal hernia at the diaphragmatic impression
Aortoenteric fistula	Hematemesis Melena	Back pain Fever	Infectious aortitis (syphilis, tuberculosis) Prosthetic aortic graft	Endoscopy is important, primarily to exclude other, more

	Hematochezia (indicates brisk bleeding) May have a "herald" bleed followed by massive bleeding	Signs of sepsis Pulsatile abdominal mass Abdominal bruit	Atherosclerotic aortic aneurysm Penetrating ulcers Tumor invasion Trauma Radiation injury Foreign body perforation	common causes of acute upper GI bleeding Endoscopy with an enteroscope or side-viewing duodenoscope may reveal a graft, an ulcer or erosion at the site of an adherent clot, or an extrinsic pulsatile mass in the distal duodenum or esophagus
Tumors				
Upper GI tumors	Hematemesis Melena Hematochezia (indicates brisk bleeding) Occult blood loss	Weight loss Anorexia Nausea/vomiting Early satiety Epigastric pain Dysphagia (for tumors in the esophagus or proximal stomach) Gastric outlet obstruction Palpable mass Paraneoplastic manifestations: ▪ Diffuse seborrheic keratoses ▪ Acanthosis nigricans ▪ Membranous nephropathy ▪ Coagulopathy	Virtually any tumor type may bleed Benign tumors: ▪ Leiomyoma ▪ Lipoma ▪ Polyp (hyperplastic, adenomatous, hamartomatous, inflammatory) Malignant tumors: ▪ Adenocarcinoma ▪ GI stromal tumors ▪ Lymphoma ▪ Kaposi sarcoma ▪ Carcinoid ▪ Melanoma ▪ Metastatic tumors	Ulcerated mass in the esophagus, stomach, or duodenum In gastric malignancies, the folds surrounding the ulcer crater may be nodular, clubbed, fused, or stop short of the ulcer margin; the margins may be overhanging, irregular, or thickened Bleeding lymphoma may appear as an ulcerated mass or polypoid lesion or as a gastric ulcer
Miscellaneous				
Hemobilia	Hematemesis Melena Hematochezia (indicates brisk bleeding)	Biliary colic Jaundice (obstructive) Sepsis (biliary)	Past history of liver or biliary tract instrumentation and/or injury, including the following: ▪ Liver biopsy ▪ Cholecystectomy ▪ Endoscopic biliary biopsies or stenting ▪ TIPS placement ▪ Angioembolization ▪ Blunt or penetrating abdominal trauma ▪ Gallstones ▪ Cholecystitis ▪ Hepatic or bile duct tumors ▪ Intrahepatic stents ▪ Hepatic artery aneurysms ▪ Hepatic abscesses	Blood or clot emanating from the ampulla (a side-viewing duodenoscope may be required to visualize the ampulla) If a clot has formed in the bile duct, bleeding may not be appreciated until the clot is removed ERCP may reveal a filling defect in the bile duct
Hemosuccus pancreaticus	Hematemesis Melena Hematochezia (indicates brisk bleeding)	Abdominal pain Past evidence of symptoms/signs of pancreatitis Imaging evidence of pancreatitis (current or in	Chronic pancreatitis Pancreatic pseudocysts Pancreatic tumors Pancreatic pseudoaneurysm	Blood or clot emanating from the ampulla (a side-viewing duodenoscope may be required to visualize the ampulla)

		the past) Elevated amylase and lipase (current or in the past)	Therapeutic endoscopy of the pancreas or pancreatic duct: ▪ Pancreatic stone removal ▪ Pancreatic duct sphincterotomy ▪ Pseudocyst drainage ▪ Pancreatic duct stenting	Cross-sectional imaging or angiography is often required to confirm the diagnosis

CMV: cytomegalovirus; HSV: herpes simplex virus; ZES: Zollinger-Ellison syndrome; NSAID: nonsteroidal anti-inflammatory drug; HIV: human immunodeficiency virus; GI: gastrointestinal; TIPS: transjugular intrahepatic portosystemic shunt; ERCP: endoscopic retrograde cholangiopancreatography.
* If active bleeding or large amounts of residual blood are present, the characteristic endoscopic findings may be obscured.
¶ Postprandial fullness, early satiety, epigastric pain, or burning.
Δ Evidence of chronic liver disease includes jaundice, splenomegaly, ascites, thrombocytopenia, palmar erythema, spider angiomata, gynecomastia, testicular atrophy, and Dupuytren's contracture.

Graphic 103148 Version 4.0

Large duodenal ulcer

Endoscopic view of a relatively large and deep ulcer in the duodenum, without evidence of a visible vessel or active bleeding (a black spot in the base of the ulcer can be seen).

Graphic 86668 Version 1.0

Duodenal ulcer with a visible vessel

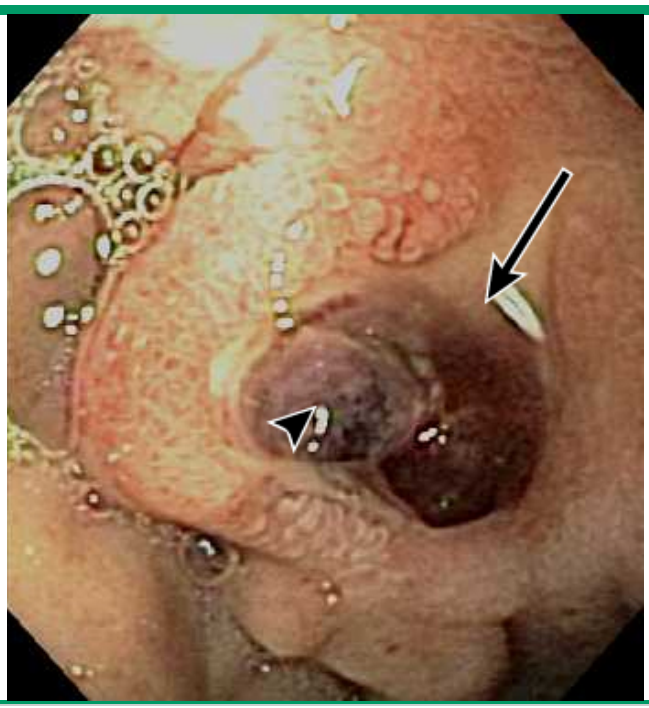

Endoscopic view of a relatively small duodenal ulcer (arrow) with a large visible vessel at its inferior portion (arrowhead).

Graphic 87064 Version 1.0

Severe esophagitis

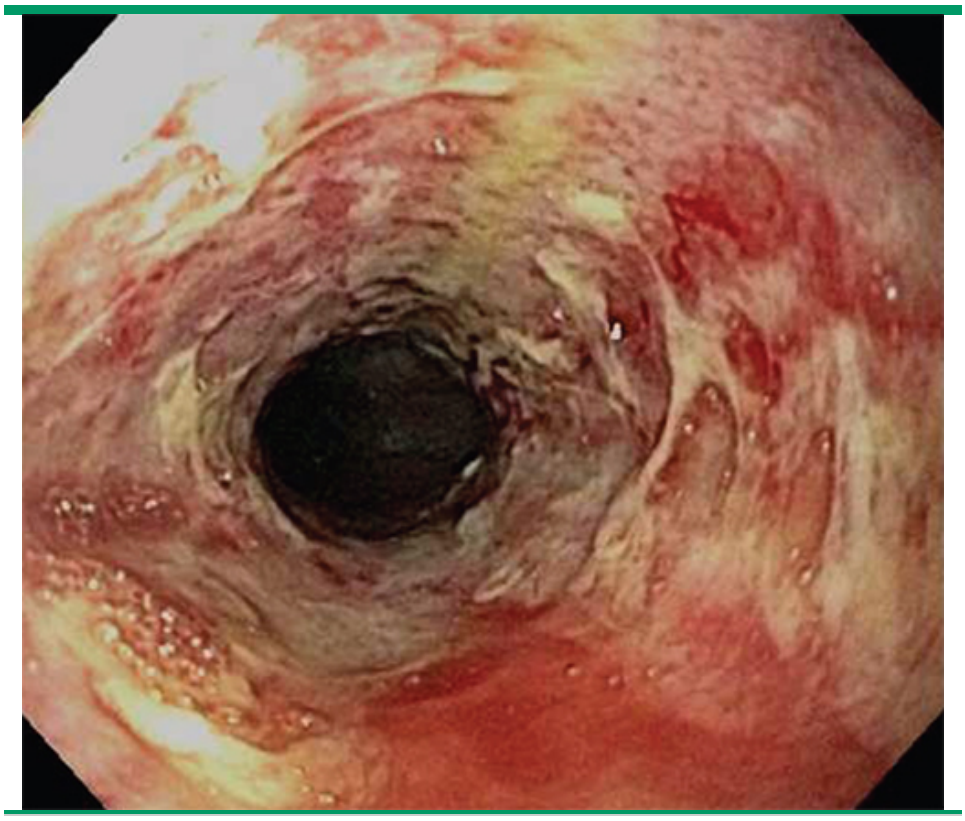

Endoscopic view of severe reflux esophagitis in a patient who presented with upper gastrointestinal bleeding.

Graphic 87065 Version 1.0

Esophageal varices

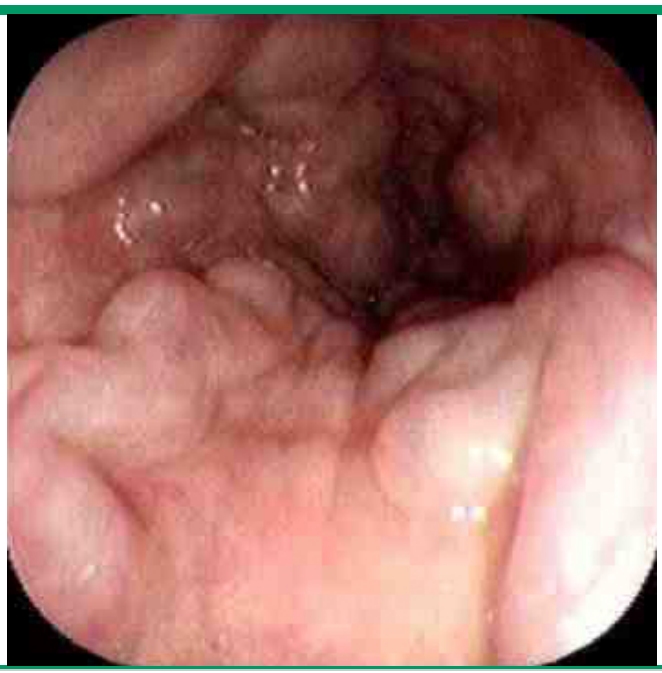

Endoscopic images from a patient with esophageal varices. Varices may or may not have stigmata of bleeding. These varices are large but do not have clear stigmata of bleeding, such as red wale signs.

Graphic 87066 Version 1.0

Actively bleeding esophageal varix

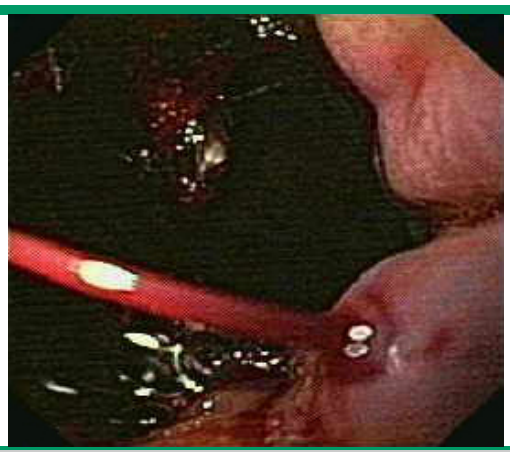

Endoscopic view of an actively bleeding esophageal varix. The varix was banded successfully, and the bleeding stopped.

Graphic 87067 Version 1.0

Gastric varix

The image obtained at the time of endoscopy reveals a typical GOV (gastro-oesophageal variceal) lesion. The GOV nomenclature is used for varices that are continuous from the esophagus to the stomach (GOV1 include those that extend less than 5 cm from the GE junction, whereas GOV2 extend for further than this length [this is an instance of GOV2]). The large grape-like structure appears to emanate from the GE junction, typical of GOV lesions. Gastric varices can also be isolated, often when they arise as a result of splenic vein thrombosis.

Graphic 87068 Version 1.0

Dieulafoy's lesion

Endoscopic view of the stomach showing a bleeding Dieulafoy's lesion.

Courtesy of Rome Jutabha, MD.

Graphic 76996 Version 1.0

Gastric Dieulafoy's lesion

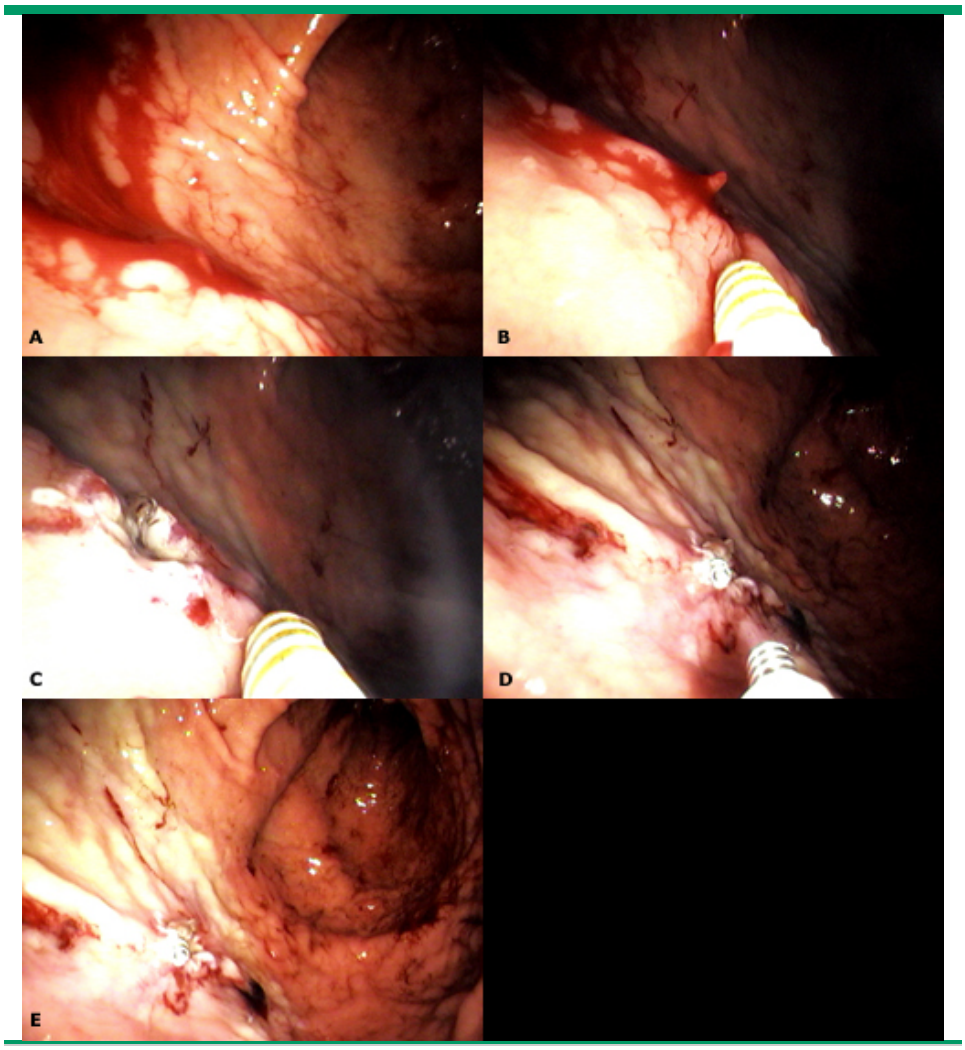

Active bleeding from a gastric Dieulafoy's lesion (A) along the proximal antrum/anterior wall. The bleeding was controlled with combination endoscopic therapy consisting of: Injection therapy with a 10 French Injector-Gold Probe (Microvasive Corp) using 1:10,000 epinephrine (B), followed by bipolar electrocoagulation at 12 Watts x 10 sec/pulse x 4 pulses using firm tamponade pressure (C), then hemoclipping x 1 (Olympus Corp) (D). India ink tatooing (E) was then performed to mark the treatment site in the event of rebleeding and facilitate localization if surgical intervention (such as wedge resection) is required.

Courtesy of Rome Jutabha, MD.

Graphic 73328 Version 1.0

Gastric antral vascular ectasia (watermelon stomach)

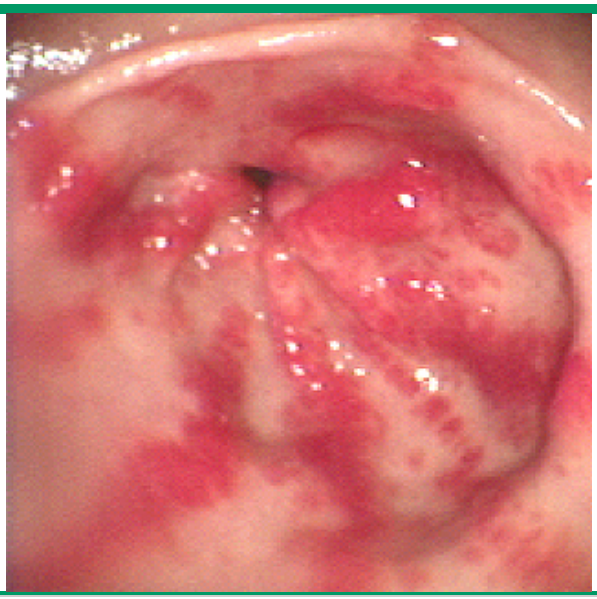

Endoscopy in a patient with gastric antral vascular ectasia (GAVE) shows the antrum and the pylorus (center) with erythematous radial stripes resembling the rind of a watermelon. The patient presented with iron deficiency anemia.

Courtesy of Laurence Bailen, MD.

Graphic 67415 Version 2.0

Gastric antral vascular ectasia

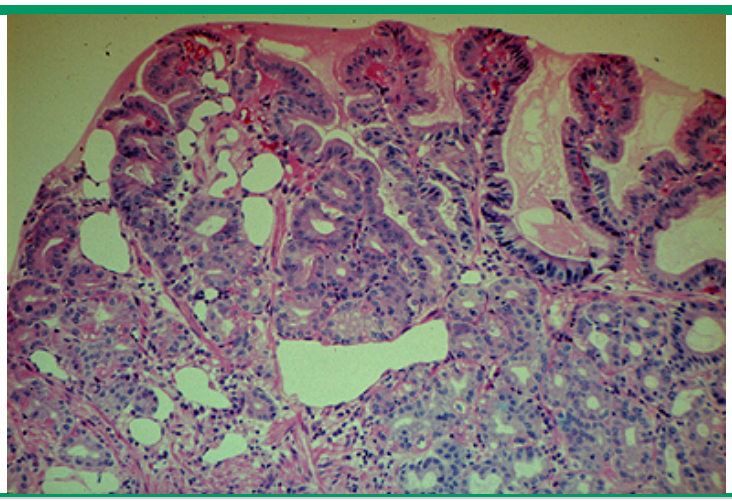

Light micrograph of gastric antral vascular ectasia shows vascular ectasia, spindle cell proliferation, and fibrohyalinosis.

Courtesy of Rome Jutabha, MD and Dennis M Jensen, MD.

Graphic 76145 Version 1.0

Gastric antral vascular ectasia (watermelon stomach)

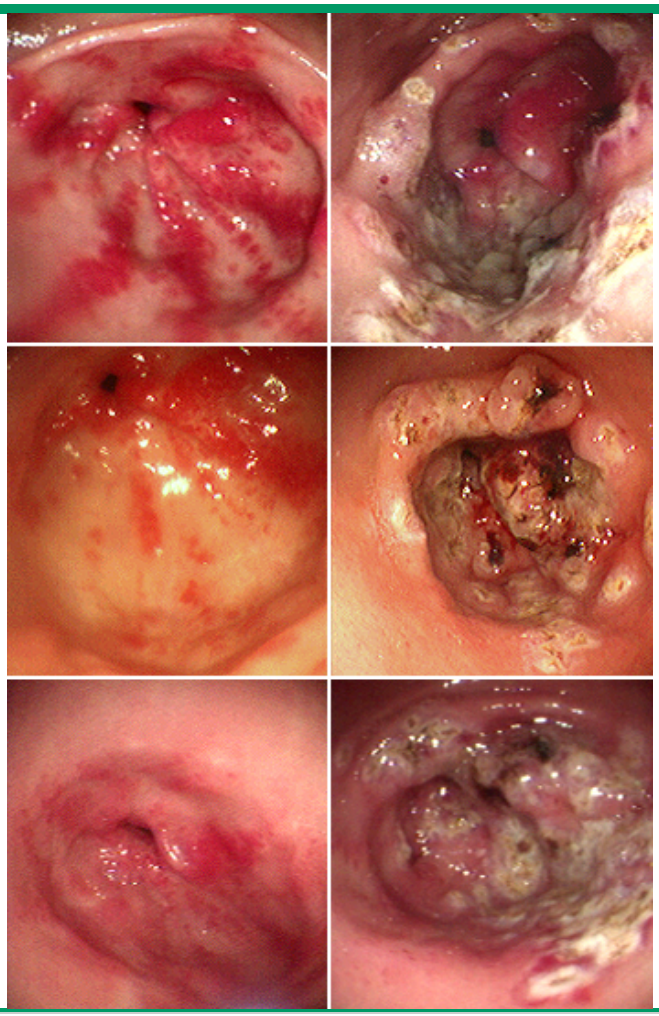

Serial endoscopic images of gastric antral vascular ectasia ("watermelon stomach"), that has been treated with argon plasma coagulation. The top row shows the original appearance of the lesions, and their appearance following initial treatment. The middle row shows the appearance following the first treatment session and after the second treatment session. The third row demonstrates the marked improvement following the first two treatment sessions, and the appearance after a third treatment session.

Courtesy of Eric D Libby, MD.

Graphic 54724 Version 2.0

Thermal coagulation of gastric antral vascular ectasia

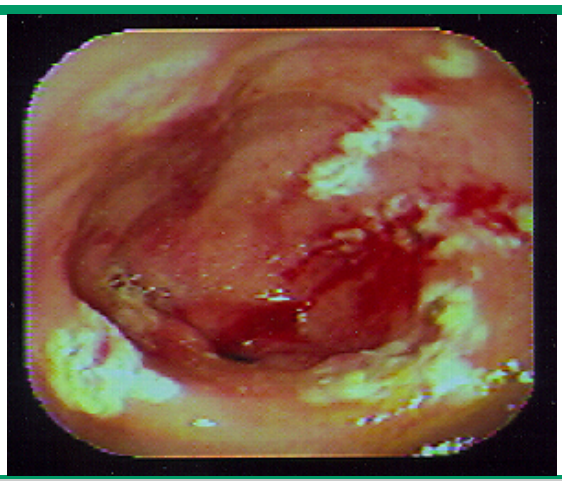

Endoscopic appearance after bipolar probe thermal coagulation of gastric antral vascular ectasia (watermelon stomach). Coagulation with the bipolar probe eventually obliterated the vascular ectasia.

Courtesy of Rome Jutabha, MD and Dennis M Jensen, MD.

Graphic 56249 Version 2.0

Gastric tumor

Endoscopic view of an ulcerated gastric adenacarcinoma.

Courtesy of Rome Jutabha, MD.

Graphic 55378 Version 1.0

Contributor Disclosures

Don C Rockey, MD Nothing to disclose **Mark Feldman, MD, MACP, AGAF, FACG** Nothing to disclose **Anne C Travis, MD, MSc, FACG, AGAF** Nothing to disclose

Contributor disclosures are reviewed for conflicts of interest by the editorial group. When found, these are addressed by vetting through a multi-level review process, and through requirements for references to be provided to support the content. Appropriately referenced content is required of all authors and must conform to UpToDate standards of evidence.

Conflict of interest policy